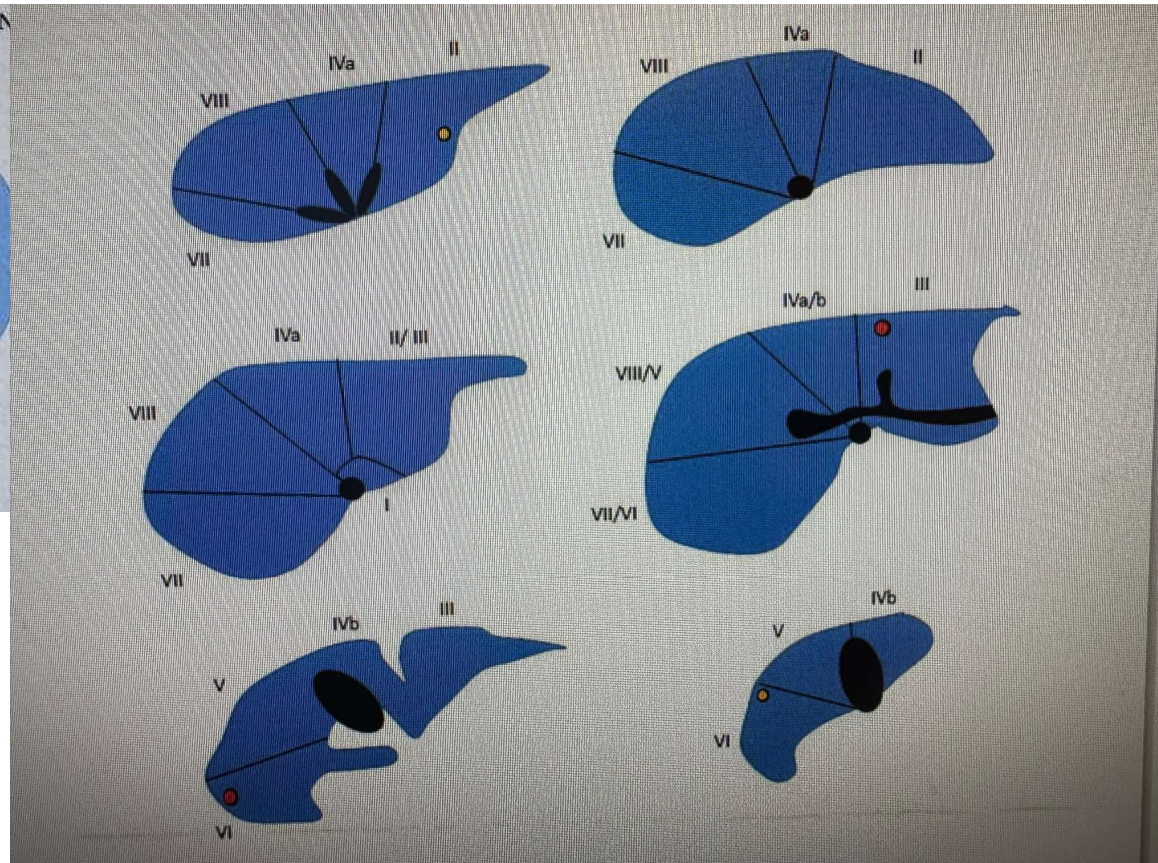
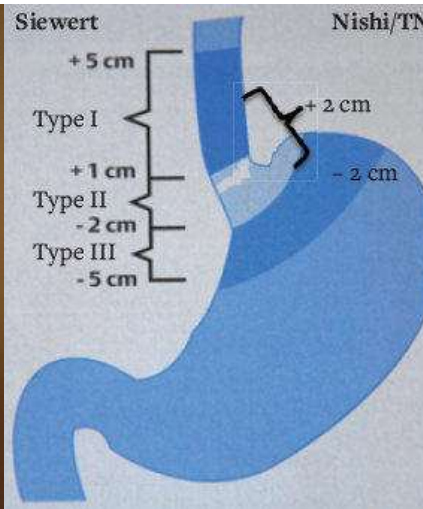
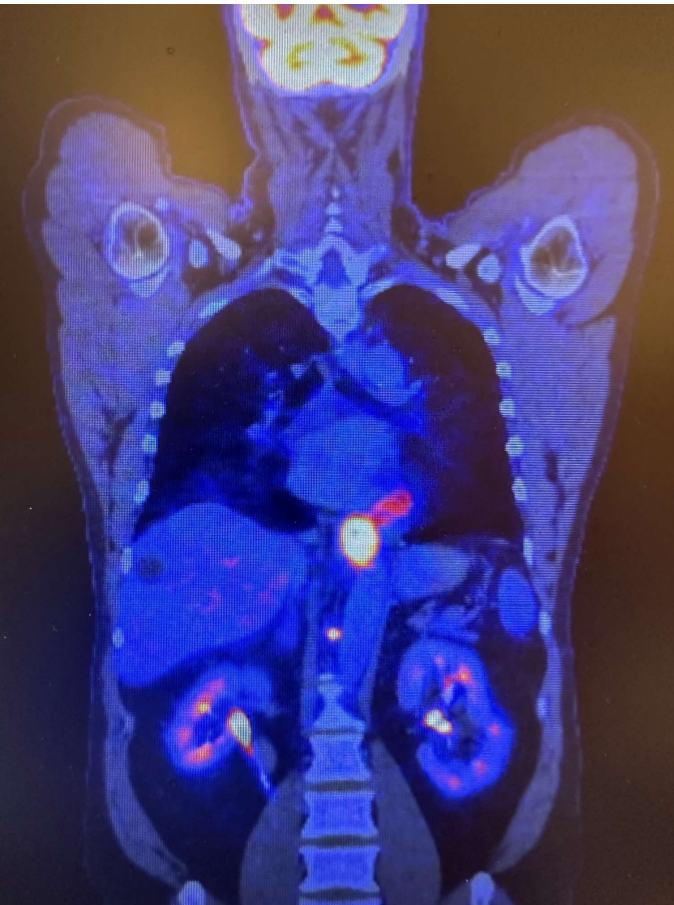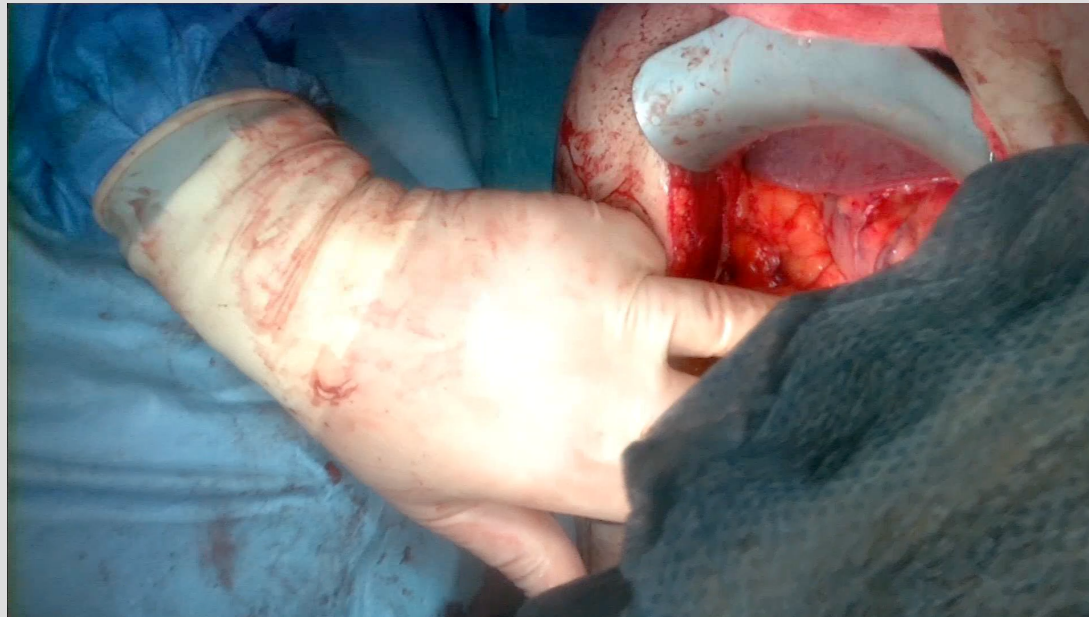


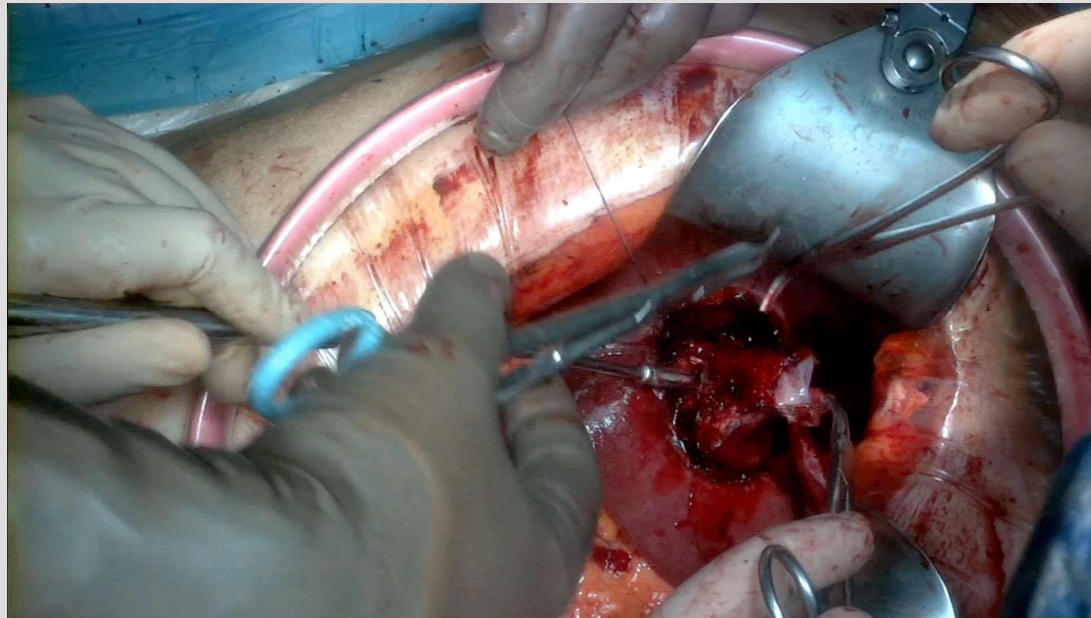
# Case report M.VM



## Laparotomy with gastrolisis



## Métastasectomie hépatique Seg.3

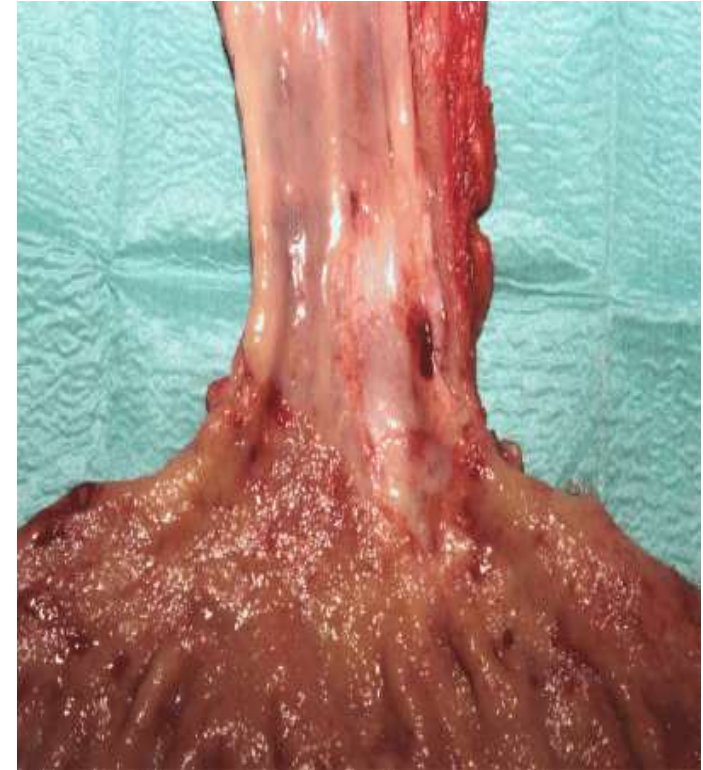

- ▶ Pas de complication postop. Sortir à 12 jour
- ▶ Qualité de vie excellent

▶ Histology:

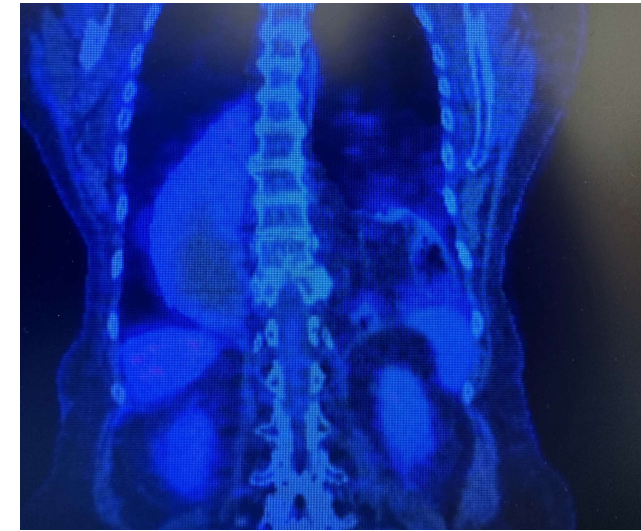
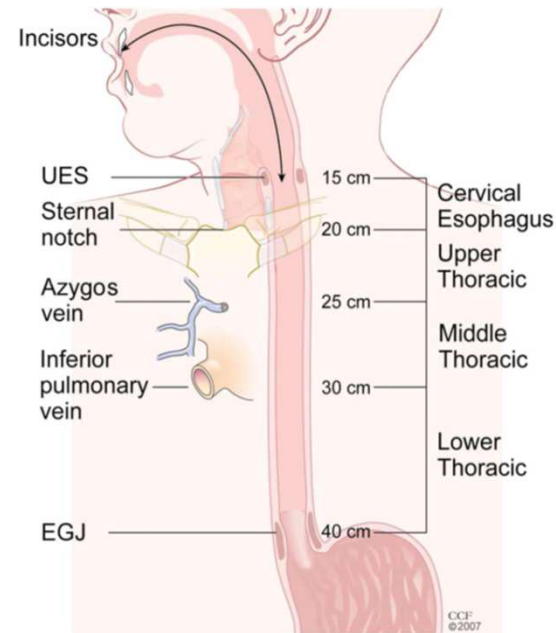
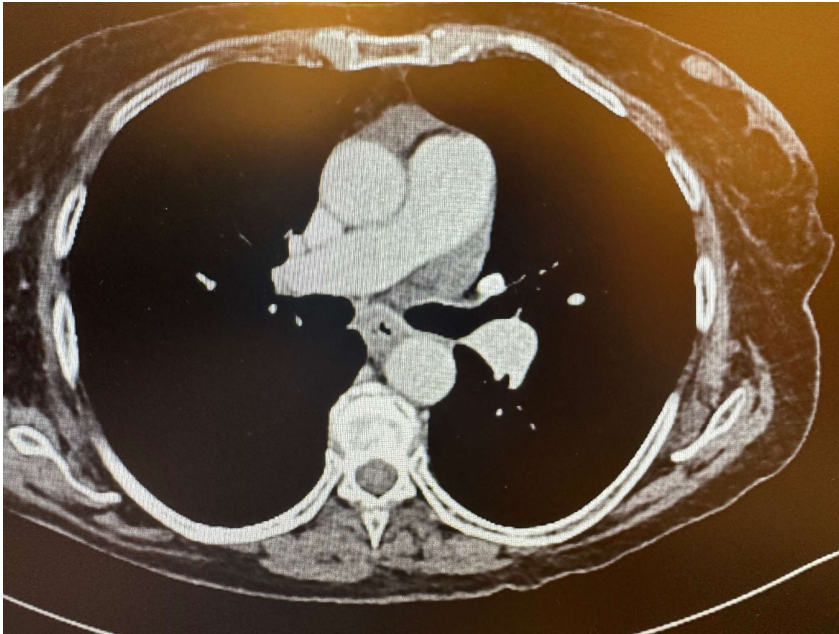
**ypT0 N0(044) L0 V0 Pn0 R0**

**Nodule hépatique:  
correspondre à une ancienne métastase en  
régression tumorale complète**



## Case report Mme.C epidermoid 27 cm 06/2020

05/2022



**Hernie diaphragmatique gauche**

**Oesophagectomie Lewis-Santý par laparoscopie et thoracotomie à droit**  
**Anastomose à 21 cm**  
**ypT0 N0 M0 R0**  
**Sortir à j12 sans complication postopératoire**